

---

## TRANSDERMAL ANAESTHESIA FOR PERCUTANEOUS TRIGGER FINGER RELEASE

Christos K. Yiannakopoulos

*Laboratory for the Research of the Musculoskeletal System  
University of Athens, Athens, Greece*

Ioannis A. Ignatiadis

*Department of Hand Surgery and Microsurgery  
KAT Hospital, Nikis 2  
Kifissia, 15125 Athens, Greece*

Received 19 June 2005; Accepted 10 November 2006

### ABSTRACT

The purpose of this study was to evaluate the safety and efficiency of transdermal anaesthesia using eutectic mixture of lidocaine and prilocaine (EMLA) in patients undergoing percutaneous trigger finger release and to compare it with lidocaine infiltration.

In this prospective, randomised study percutaneous release of the A1 annular pulley was performed to treat stenosing tenosynovitis (trigger finger syndrome) in 50 patients (50 fingers). The procedure was performed either under transdermal anaesthesia using EMLA applied transcutaneously 120 minutes prior to the operation (Group A,  $n = 25$ ) or using local infiltration anaesthesia using lidocaine (Group B,  $n = 25$ ). Pain experienced during administration of anaesthesia and during the operation was assessed using a 10-point Visual Analogue Pain Scale (VAPS), while all patients rated the effectiveness of anaesthesia with a 5-point scale.

There were no significant differences between the two groups in the VAPS during the operation ( $1.33 \pm 0.52$  versus  $1.59 \pm 0.87$ ) and the satisfaction scores ( $4.6 \pm 0.2$  versus  $4.4 \pm 0.3$ ). The VAPS score during the administration of anaesthesia was statistically significantly less in the EMLA group ( $0$  versus  $5.96 \pm 2.41$ ). All patients were satisfied with the final result of the operation.

Percutaneous trigger finger release can be performed as an office procedure with the use of EMLA avoiding the use of injectable local infiltration anaesthesia.

*Keywords:* Anaesthesia; Eutectic Mixture of Lidocaine and Prilocaine; Percutaneous Release; Trigger Finger.

## INTRODUCTION

Surgical release of the A1 annular pulley is recommended when conservative treatment of trigger finger syndrome has failed. The release can be performed either as an open procedure or percutaneously with success and without serious complications.<sup>1</sup> With either technique the use of local injectable anaesthesia is necessary. Local anaesthesia is accompanied with injection pain and occasionally with systemic symptoms attributed to the absorption of the local anaesthetic used, usually lidocaine. EMLA<sup>®</sup> cream (Astra Zeneca, Halandri, Athens, Greece) is used in patients of almost every age, from neonates to geriatric patients, to provide transcutaneous anaesthesia which enables the performance of a variety of procedures and operations, including arterial and venous cannulation, split thickness skin grafting, mechanical ulcer debridement, carpal tunnel syndrome anaesthesia, prevention of acute and chronic pain etc.<sup>2-7</sup>

The purpose of this study was to investigate the safety and efficacy of EMLA cream as an alternative method of local anaesthesia in percutaneous trigger finger release and to compare it with lidocaine infiltration.

## MATERIALS AND METHODS

A prospective, randomised trial was performed including 50 patients with stenosing tenosynovitis (trigger finger syndrome), who underwent percutaneous A1 pulley release. The study was approved from the Ethics and Research Committee of our Institution. All patients had a palpable, tender tendon nodule and characteristic mechanical triggering. On the whole, 50 trigger fingers were treated surgically. The patients were randomly allocated in two Groups. In Group A ( $n = 25$ ) skin anaesthesia was provided using EMLA and in Group B ( $n = 25$ ) the skin was infiltrated with 3 ml lidocaine 1%. The demographical data of all patients are presented in Table 1.

The patient arrived at the office two and a half hours prior to the scheduled operation time, where a thick layer of 5 mg EMLA<sup>®</sup> cream was applied on the palmar skin corresponding to the location of the A1 pulley to be released and the cream was then covered with an occlusive dressing (Tegaderm, 3M, St. Paul, MN). The dressing was removed prior to the operation and the cream was wiped off. The operations were performed under forearm tourniquet using the tip of an 18-gauge needle, mounted on a 3 ml syringe. The surface

**Table 1 Patient Demographic and Results.**

	Group A (EMLA) $n = 25$	Group B (Lidocaine) $n = 25$
Males	9	11
Females	15	13
Age, years, Mean $\pm$ SD	58.8 $\pm$ 12.5	61.1 $\pm$ 15.9
Operation Duration, Minutes, Mean $\pm$ SD	3.2 $\pm$ 1.5	3.3 $\pm$ 1.1
VAPS, Anaesthesia, Mean $\pm$ SD	0*	5.96 $\pm$ 2.41
VAPS, Operation, Mean $\pm$ SD	1.33 $\pm$ 0.52	1.59 $\pm$ 0.87
Patient Satisfaction, Mean $\pm$ SD	4.6 $\pm$ 0.2	4.4 $\pm$ 0.3

VAPS = Visual analogue pain scale; EMLA = Eutectic mixture of local anaesthetics; \* $p < 0.05$ .

landmarks on the skin of the palm were marked, the skin was cleaned and the finger MCP joint was held in hyperextension by an assistant. The proximal and distal ends of the A1 pulley were determined and marked using surface landmarks.<sup>8</sup> The position of the needle was confirmed by asking the patient to flex and extend the corresponding finger. Intratendinous position of the needle caused mild pain. The proximal end and the stoma of the A1 pulley were identified with palpation and release was performed in a proximal to distal direction. A typical grating sound and a similar sensation during A1 pulley release ensured the success of the release. The patient was asked to flex and extend the finger. Absence of triggering was regarded as a sign of complete release. The wound was covered with a soft compressive bandage and the patient was advised to keep his/her hand elevated for 48 hours, while active finger motion was encouraged as soon as the patient was comfortable.

Pain experienced during the administration of anaesthesia and during the operation was assessed by an independent research nurse using a 10-point Visual Analogue Pain Scale (VAPS), while all patients rated the effectiveness of anaesthesia during the procedure on a 5-point scale. A score of 1 was considered as a measure of insufficient anaesthesia and a score of 5 as a measure of excellent anaesthesia. Normally distributed continuous data were analysed with a paired Student's *t*-test and categorical data were analysed with the chi-square test with Yates' continuity correction. A *p* value of  $<0.05$  was considered statistically significant.

## RESULTS

The average duration of the operation in Groups A and B was  $3.2 \pm 1.5$  and  $3.4 \pm 1.2$  minutes, respectively and no case had to be cancelled because of insufficient anaesthesia (Table 1). The two groups did not differ significantly in age, sex and finger operated. There were no significant intraoperative complications or any recurrences. There were no infections, nerve or vessel injuries or incomplete pulley release. Skin blanching was noted in four patients upon removal of the occlusive dressing in Group A. There were no significant differences between the two groups in the VAPS during the operation and satisfaction scores (Fig. 1). The difference in the VAPS score during administration of anaesthesia was statistically significant in favour of the EMLA group. The VAPS score for anaesthesia was in the EMLA group 0, while in the infiltration group  $5.96 \pm 2.41$ . The mean VAPS score, representing the level of pain during the operation was in Group A  $1.33 \pm 0.52$  and in Group B  $1.59 \pm 0.87$ . This difference was not significant. All patients who received infiltration anaesthesia considered the injection as the most painful part of the procedure. The patients were reviewed one, six and 12 weeks after the operation. All patients returned to work and their previous activities within two days. Full unobstructed range of finger flexion was obtained and the final cosmetic result was excellent. In most patients, only a small spot of skin discolouration could be noted at the site of the needle insertion. All patients were satisfied with the final result of the operation.

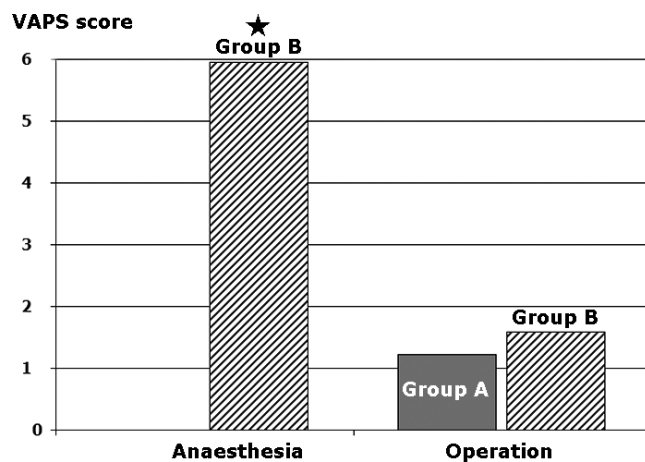


Fig. 1 The VAPS scores between Groups A and B ( $*p < 0.05$ ).

## DISCUSSION

Percutaneous trigger finger release is a safe procedure and its efficacy has been proved by clinical and cadaveric studies.<sup>9-11</sup> Complications following surgical management of trigger finger are not very common but when occurring they may be severe.<sup>11,12</sup> The most important complications are digital nerve transection, inadvertent A2 pulley release and tendon bowstringing. Complications such as scar tenderness, infection, haematoma and stiffness may be more common after an open procedure, while complications such as digital nerve injury or tendon bowstringing may appear both after open and percutaneous procedures. Probably, the most common complications after percutaneous release using a needle are incomplete release and flexor tendon injury. The first complication can be prevented if complete resolution of triggering is ascertained with finger movement. The second complication is usually not significant and can be avoided with a meticulous technique and increasing experience.<sup>8,9,11,12</sup>

Local anaesthetics are used whenever a surgical procedure or intervention is going to cause pain and discomfort to the patient. The most common hand operations are carpal tunnel decompression and trigger finger release, which is performed as office procedures under local anaesthesia. Local anaesthesia can be performed using an appropriate local anaesthetic agent administered in three ways: topical application, local infiltration and field block.<sup>11</sup> Infiltration anaesthesia is effective but has the disadvantage of painful and uncomfortable injections, especially when large or sensitive areas are to be anaesthetised. Local infiltration anaesthesia may also have several complications: anaesthesia failure, pain or burning on injection, haematoma, infection, persistent anaesthesia, overdose, hypersensitivity reactions, etc.<sup>2,11</sup> EMLA, an acronym for Eutectic Mixture of Local Anesthetics containing lidocaine 2.5% and prilocaine 2.5%, can be used prior to local anaesthetic infiltration to reduce pain associated with procedures such as carpal tunnel syndrome and prominent ear correction.<sup>2,12</sup>

With the use of EMLA percutaneous trigger finger release can be performed easily and safely in the outpatient clinic or in the office, reducing the costs of surgical treatment. The only disadvantage is the need to apply the cream at least 120 minutes prior to the operation to optimise its effectiveness. In our study, EMLA has provided adequate anaesthesia to perform percutaneous release and was well tolerated. The most important limitations in the use of EMLA is the delay necessary to obtain anaesthesia since skin penetration of topical anaesthetics is

time-dependent and the limited depth of dermal anaesthesia, which is approximately 5 mm after 90 minutes.<sup>13</sup>

EMLA use is virtually complication-free and the most common side-effect is transient skin blanching noted upon removal of the dressing.<sup>14</sup> Blood levels of lidocaine and prilocaine after application of EMLA cream are well below toxic levels.<sup>15</sup> Methaemoglobinaemia attributed to a metabolite of prilocaine prohibits its use in infants younger than six months.<sup>16</sup>

In conclusion, release using EMLA anaesthesia is safe, non-invasive and more comfortable than infiltration anaesthesia. The major drawback is the necessity to apply the cream at least 120 minutes before the operation. The two to three hours of extra time may be a substantial inconvenience for many patients and this should be discussed with them before scheduling the operation.

## References

1. Benson LS, Ptaszek AJ, Injection versus surgery in the treatment of trigger finger, *J Hand Surg [Am]* **22**:138–144, 1997.
2. Avramidis K, Lewis JC, Gallagher P, Reduction in pain associated with open carpal tunnel decompression, *J Hand Surg [Br]* **25**:147–149, 2001.
3. Galinkin JL, Rose JB, Harris K, Watcha MF, Lidocaine iontophoresis versus eutectic mixture of local anesthetics (EMLA) for IV placement in children, *Anesth Analg* **94**:1484–1488, 2002.
4. Lok C, Paul C, Amblard P, Bessis D, Debure C, Faivre B, Guillot B, Ortonne JP, Huledal G, Kalis B, EMLA cream as a topical anesthetic for the repeated mechanical debridement of venous leg ulcers: a double-blind, placebo-controlled study, *J Am Acad Dermatol* **40**:208–213, 1999.
5. Lawrence T, Desai VV, Topical anaesthesia to reduce pain associated with carpal tunnel surgery, *J Hand Surg [Br]* **27**:462–464, 2002.
6. Olday SJ, Walpole R, Wang JY, Radial artery cannulation: topical amethocaine gel versus lidocaine infiltration, *Br J Anaesth* **88**:580–582, 2002.
7. Wahlgren CF, Lillieborg S, Split-skin grafting with lidocaine-prilocaine cream: a meta-analysis of efficacy and safety in geriatric versus non-geriatric patients, *Plast Reconstr Surg* **107**:750–756, 2001.
8. Wilhelmi BJ, Snyder N, Verbesey JE, Ganchi PA, Lee WP, Trigger finger release with hand surface landmark ratios: an anatomic and clinical study, *Plast Reconstr Surg* **108**:908–915, 2001.
9. Bain GI, Turnbull J, Charles MN, Roth JH, Richards RS, Percutaneous A1 pulley release: a cadaveric study, *J Hand Surg [Am]* **20**:781–784, 1995.
10. Eastwood DM, Gupta KJ, Johnson DP, Percutaneous release of the trigger finger: an office procedure, *J Hand Surg [Am]* **17**:114–117, 1992.
11. Smith DW, Peterson MR, DeBerard SC, Local anesthesia. Topical application, local infiltration, and field block, *Postgrad Med* **106**:57–60, 1999.
12. Slator R, Goodacre TE, EMLA cream on the ears — is it effective? A prospective, randomised controlled trial of the efficacy of topical anaesthetic cream in reducing the pain of local anaesthetic infiltration for prominent ear correction, *Br J Plast Surg* **48**:150–153, 1995.
13. Bjerring P, Arendt-Nielsen L, Depth and duration of skin analgesia to needle insertion after topical application, *Br J Anaesth* **64**:173–177, 1990.
14. Stymne B, Lillieborg S, Plasma concentrations of lignocaine and prilocaine after a 24-hour application of analgesic cream (EMLA) to leg ulcers, *Br J Dermatol* **145**:530–534, 2001.
15. Buckley MM, Benfield P, Eutectic lidocaine/prilocaine cream. A review of the topical anaesthetic/analgesic efficacy of a eutectic mixture of local anaesthetics (EMLA), *Drugs* **46**:126–151, 1993.