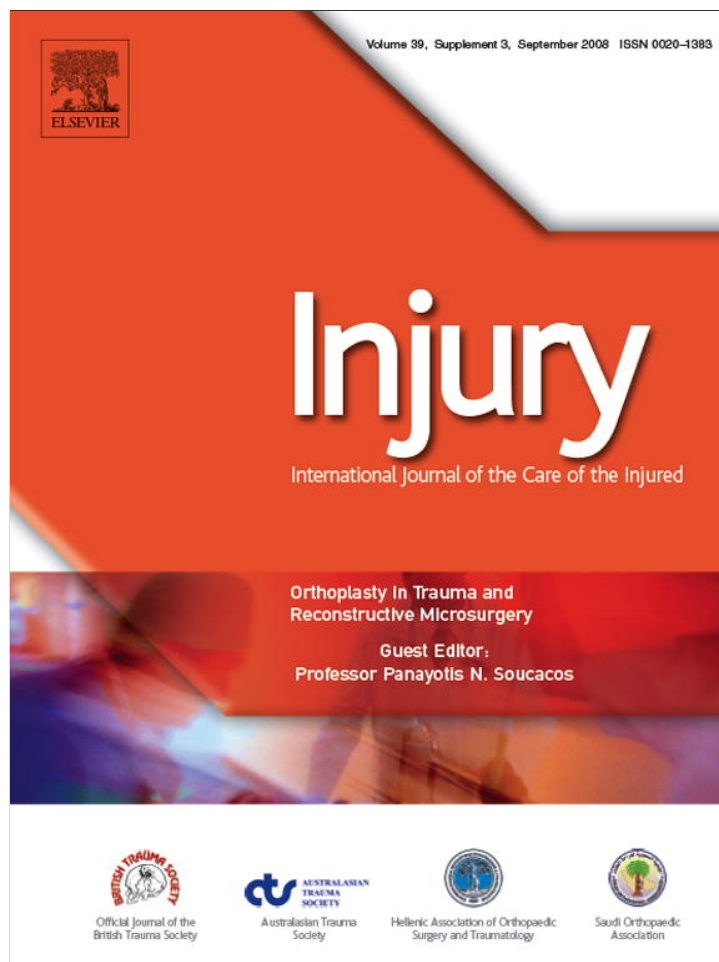

This article appeared in a journal published by Elsevier. The attached copy is furnished to the author for internal non-commercial research and education use, including for instruction at the authors institution and sharing with colleagues.

Other uses, including reproduction and distribution, or selling or licensing copies, or posting to personal, institutional or third party websites are prohibited.

In most cases authors are permitted to post their version of the article (e.g. in Word or Tex form) to their personal website or institutional repository. Authors requiring further information regarding Elsevier's archiving and manuscript policies are encouraged to visit:

<http://www.elsevier.com/copyright>



Treatment of complex hand trauma using the distal ulnar and radial artery perforator-based flaps

Ioannis A. Ignatiadis^{a,*}, Andreas F. Mavrogenis^b, Adrian M. Avram^c,
Alexandru V. Georgescu^c, Manuel Llusca Perez^d,
Nikolaos E. Gerostathopoulos^a, Panayotis N. Soucacos^b

^aDepartment of Upper Limb and Hand Surgery and Microsurgery, KAT Hospital, Athens, Greece

^bFirst Department of Orthopaedics, Athens University Medical School, Athens, Greece

^cDepartment of Plastic Surgery, Rehabilitation Hospital, Cluj Napoca "Iuliu Hatieganu"
University of Pharmacy and Medicine, Cluj, Romania

^dDepartment of Anatomy, University of Barcelona Medical School, Spain

KEYWORDS

Hand trauma;
Perforators of distal
ulna and radial
arteries;
Perforator flaps;
Fascioseptocutaneous
flaps

Summary The clinical value of distal ulnar or radial artery adipofascial perforator flaps is shown in a series of 30 patients with severe hand and wrist injuries and major soft tissue defects requiring coverage. There were 22 men and 8 women, aged 16–73 years. The defects were dorsal and/or palmar, with or without transpalmar or transcarpal amputation, or amputation of the thumb and/or the digits. Tendon injuries have been treated primarily or secondarily, or reconstructed using silicon rods. In all cases, after surgical debridement of the wound, reconstruction of the defect was done using distal ulnar (21 patients, in 3 patients primary reconstruction) and distal radial artery (11 patients; in 2 patients primary reconstruction and in 2 patients after necrosis of distal ulnar perforator flap) adipofascial perforator flaps. Minimum follow-up was 6 months. Two ulnar flap showed partial necrosis and were revised successfully by distal radial adipofascial perforator flaps. One radial and one ulnar flap showed 50% and 60% necrosis, respectively, and were revised by groin flaps. All donor sites healed uneventfully. Functional and cosmetic result was very good in 15 patients and good or satisfactory in the remaining. Range of motion of the wrist and hand joints was almost within normal limits (less than 25 degrees extension or flexion deficits). Distal ulnar and radial artery adipofascial perforator flaps for traumatic defects of the hand and wrist offer several advantages compared to other local flaps; they are easy to obtain and cover effectively both dorsal and palmar defects without significant functional deficits or donor site complications to the upper limb.

© 2008 Elsevier Ltd. All rights reserved.

* Corresponding author at: Department of Upper Limb and Hand Surgery and Microsurgery, KAT Hospital, 2 Nikis Street, 14561 Kifissia, Athens, Greece. Tel.: +30 210 6280374; fax: +30 210 6280384.

E-mail address: ignatioa@yahoo.com (I.A. Ignatiadis).

Introduction

The forearm fascial adipofascial or septocutaneous vascularised flaps based on distal perforators of the ulnar or radial arteries are much expanded in the last decade for covering hand and wrist defects without scarifying major vascular shafts or causing bad aesthetic result at the donor site. With the advent of perforator flap surgery it has been made possible to reduce donor site morbidity, improving the functional and aesthetic result.^{5,6,38} In addition, preoperative imaging studies such as angiography and Doppler or triplex ultrasonography are not necessary.^{5,6,9,13,14,17,18,24,26,28,29,36,38}

Use of the fascial flap is indicated in patients with hand soft tissue defects. The reversed ulnar forearm flap^{17,24,26,29,36} as described by Lovie, is a septocutaneous flap based on the septocutaneous perforators of the ulnar artery but it can also be harvested as a fascial flap.^{26,29} The ulnar forearm flaps present the advantage of a thin and elastic fascia and can be harvested with bone, muscle and sensory or motor nerves.²⁴ The main trunk of the pedicle is called the ulnodorsal artery and arises from the ulnar artery at a distance of 3–5 cm proximal to the pisiform. The artery passes beneath flexor carpi ulnaris and divides into three branches. The proximal branch supplies the distal part of flexor carpi ulnaris, and the distal branch supplies the pisiform. The middle branch supplies the skin and divides into two thin arterial branches that pierce the fascia. The ascending branch passes between ulna and flexor carpi ulnaris, supplying the skin of the medial aspect of the distal forearm and the descending branch accompanies the sensory dorsal branch of the ulnar nerve supplying the skin.

Over the past decade, the distal radial artery perforator flap based on the small perforators around the radial styloid process and the longitudinal chain-linked vascular plexuses has been described.^{9,13,14,18,27} Since then, it has become a very popular loco-regional flap for hand reconstruction. By using these flaps instead of the traditional Chinese flap one can overcome the two major disadvantages of the Chinese donor site area: the sacrifice of a major artery and the displeasing scar deformity of the split-skin graft used for wound closure.

The purpose of this study is to describe the use of the distal ulnar and radial artery adipofascial perforator flaps for reconstruction of severe open injuries of the hand, and to discuss the indications and advantages of these flaps.

Patients and methods

Thirty patients with severe open hand injuries were admitted and treated at the authors' institution by adipofascial distal ulnar or radial artery perforator-based flaps. There were 22 men and 8 women, aged 16–73 years. The defects were dorsal and/or palmar, with or without transpalmar or transcarpal amputation, or amputation of the thumb and/or the digits, and tendon injuries and fractures. All dorsal defects were associated with fractures that were primarily fixed using Kirschner wires, mini external fixators or plates. Tendon injuries have been treated primarily or secondarily, or reconstructed using silicon rods. All except one patient with a gunshot injury of the hand (patient 9) were operated immediately or within 2–4 weeks after the injury. Patients' details regarding age and gender, mechanism of injury, type and location of the defects, associated injuries, flap type and post-operative result are shown in Table 1.

In all cases, after surgical debridement of the wound, the defect was measured and the flaps were reflected on the defect. Using microsurgical technique and surgical loupes magnification, we performed adipofascial perforator flaps based on the distal ulna artery in 21 patients (in 3 patients immediately after injury), and the distal radial artery in 11 patients [in 2 patients immediately after the injury and in 2 patients after partial necrosis of the initially performed distal ulnar artery perforator flaps (patients 6 and 12)].

In distal ulnar artery perforator flaps, the incision was on the ulnar side of the wrist and forearm overlying the tendon of flexor carpi ulnaris muscle. The pisiform was identified and the pedicle was located emerging within 2–5 cm. Subdermal dissection allowed exposure of the fascia and the subcutaneous tissue was preserved. The flap was released on its radial side and retracted progressively until the underlying flexor carpi ulnaris muscle was revealed. The pedicle can be seen in the distal third of the flap. After locating the pedicle, the ulnar side of the flap was released maintaining a distal hinge. Simple rotation of the flap permits coverage of the defect located at the midpalm or the proximal two thirds of the dorsum of the hand.

The distal radial artery septocutaneous perforator flaps were designed almost as the Chinese traditional flap. The distal radial artery perforator flap is based on the small perforators of the distal radial artery (approximately 10 small perforators, 0.3–0.5 mm in diameter) and the longitudinal chain-linked vascular plexuses (suprafascial, paraneural, and perivenous) around the radial styloid process. The pivot point was designed at 1–2 cm proximal to

Table 1 Details of the 30 patients with compound hand trauma and soft tissue defects treated with distal ulnar and radial artery adipofasciocutaneous perforator flaps

Patients	Age, gender	Mechanism of injury	Location and type of defect	Tendon injury and treatment	Fractures	Initial treatment	Final treatment	Final result
1	38, M	Work accident	Dorsal	—	Metacarpals	Direct closure	At 3 weeks, ulnar flap	Very good
2	23, F	Motor vehicle accident	Dorsal	Extensors of fingers, tendon graft	Metacarpals, Galeazzi	Split thickness skin graft	At 2 weeks, ulnar flap	Good
3	25, M	Work accident	Amputation	Extensors and flexors, suture	—	Transpalmar replantation	At 2.5 weeks, ulnar flap	Very good
4	40, M	Motor vehicle accident	Dorsal	Extensors, silicon rods	Radius and ulna	Split thickness skin graft	At 4 weeks, ulnar flap	Very good
5	42, M	Work accident	Palmar	—	—	Ulnar nerve repair	At 3 weeks, ulnar flap	Good
6	35, F	Work accident	Radial	EPL, tendon transfer	First metacarpal	Split thickness skin graft, ulnar flap	At emergency, ulnar flap, necrosis, at 2 weeks radial flap	Good
7	67, F	Work accident	Dorsal	—	Metacarpals	Direct closure	At 2.5 weeks, ulnar flap	Very good
8	54, M	Motor vehicle accident	Dorsal and palmar	Extensors and flexors	Transcarpal amputation, skin necrosis	Amputation, skin closure	At 2 weeks, ulnar flap	Good
9	33, M	Gunshot	Dorsal	Extensors, silicon rods	Metacarpals	Full thickness skin graft	At 7 months, ulnar flap	Very good
10	24, F	Work accident	Dorsal	Extensors, suture	Metacarpals	Split thickness skin graft	At 2 weeks, ulnar flap	Very good
11	28, F	Work accident	Distal, transpalmar amputation	Extensors and flexors	Amputation of two to five fingers	Revascularization attempt (50% successful)	At 2 weeks, ulnar flap	Very good
12	40, F	Motor vehicle accident	Dorsal, wrist	Extensors	Radius-epiphyseal, carpal bones	External fixation, ulnar flap, split thickness skin graft	At emergency, ulnar flap, necrosis, at 15 days radial flap	Good
13	52, M	Motor vehicle accident	Palmar	Flexors, silicon rods	Metacarpals	K-wire fixation, skin closure	At 4 weeks, radial flap	Good
14	29, M	Motor vehicle accident	Transpalmar degloving	Flexors	Fingers	K-wire fixation, skin closure	At 1 week, ulnar flap	Satisfactory
15	24, M	Gunshot	Dorsal radial	Flexors	Index	External fixation, radial flap	At emergency, radial flap	Very good
16	27, M	Explosion	Palmar radial	Flexors	First ray partial-thumb amputation	Radial flap	At emergency, radial flap	Very good
17	62, M	Work accident	Palmar radial	Flexors	Thumb and index amputation	Skin closure-graft	At emergency, ulnar flap	Very good

18	16, M	Work accident	Ulnar, fifth ray amputation	—	Fifth metacarpal	Ray amputation	At 2 weeks, ulnar flap	Very good
19	24, M	Work accident	Ulnar, fourth and fifth ray amputation	—	Metacarpals	K-wire fixation	At 3 weeks, ulnar flap	Good
20	73, M	Work accident	Palmar	—	Third ray amputation	Ray amputation, skin closure	At 10 days, radial flap	Satisfactory
21	32, M	Explosives, fireworks	Palmar	Thenar	—	Debridement, left skin open	At 5 days, radial flap	Good
22	29, F	Work accident	Dorsal radial	Extensors	Radius and humerus	External fixation, skin closure	At 10 days, ulnar flap	Very good
23	22, M	Work accident	Transmetacarpal amputation	—	All metacarpals	Revascularization attempt	At 1 week, ulnar flap	Very good
24	29, M	Ski-sea	Thumb avulsion	—	Thumb degloving	At emergency, radial flap, kite flap	Skin graft	Good
25	63, M	Work accident	All fingers crush injury	—	Thumb and finger compromise	At emergency, debridement, left open wound	Radial flap after fingers amputation, partially failed (50%), groin flap	Good
26	72, M	Gunshot	Palm	Extensors 2,3,4	Second, third, metacarpals defects	Chinese flap failed	At 1 week, ulnar flap, partially failed (60%), groin flap	Very good
27	40, M	Work accident	Thenar crush injury, index open fracture	—	Index proximal phalanx	K-wire fixation (thumb), external mini fixator (index)	At emergency, radial flap	Good
28	23, M	Work accident	Palmar, ulnar	—	Fifth ray amputation	Ray amputation, skin closure	At 10 days, ulnar flap	Good
29	31, M	Explosives, fireworks	Palmar	Thenar	—	Debridement, left skin open	At 7 days, radial flap	Satisfactory
30	33, F	Work accident	Dorsal	Extensors	—	Skin closure, necrosis	At 10 days, ulnar flap	Very good

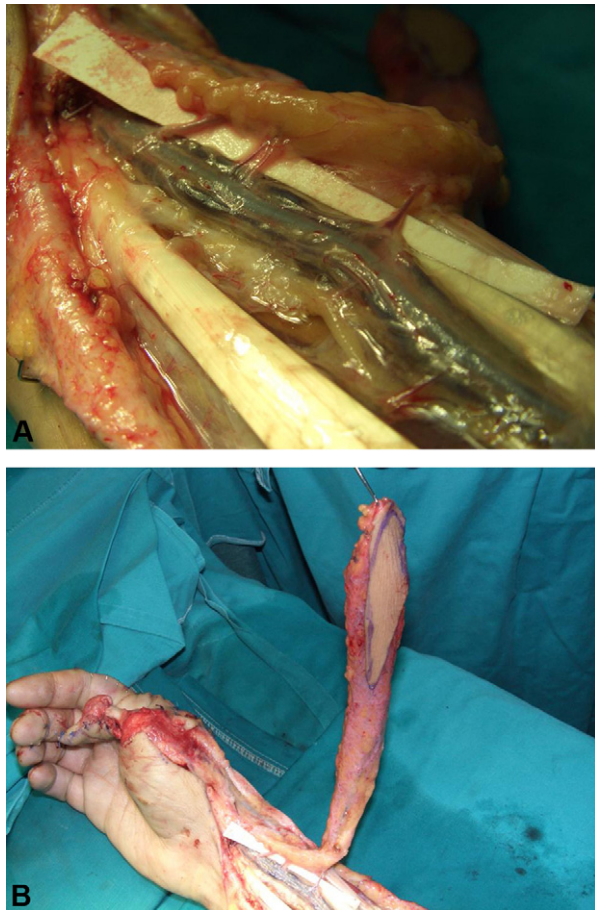


Figure 1 (A and B) A 29-year-old man with a degloving injury of the right thumb (patient 24). One stage immediate reconstruction was done using the distal radial artery fasciocutaneous perforator flap. The peristyloid distal radial artery perforators emerge at the base of the flap. The thumb palmar aspect was covered using the kite flap.

the radial styloid (Fig. 1). The skin island and the adipofascial pedicle measured 6–20 cm in length, with the adipofascial pedicle measuring 3–6 cm in width. The cephalic vein has no positive role for venous drainage in distally based flaps.

We performed 11 distal radial artery adipofascial perforator-based flaps (Fig. 2). In two patients, the radial flap was primarily performed as the initial treatment (patients 15 and 16); in another 2 patients the radial perforator flap was applied for the management of failed distal ulnar artery-based perforator fascial flap (patients 6 and 12). In one patient with degloving injury of the thumb (patient 24), we performed both Kite (neurovascular) and distal radial artery perforator flaps for covering both palmar and dorsal aspects, respectively (Fig. 1).

In a patient with thumb blast injury from a fire-work (patient 16), we treated an amputated thumb by covering the first metacarpal with a composite

adipofasciocutaneous distal radial artery perforator flap, thereby creating a first web space (Fig. 3).

In all cases, flaps were harvested within 35–45 min. The donor site was covered with split on full thickness skin graft. The hand and wrist were immobilised for 2 weeks in a plaster splint. Post-operatively, all patients received instructions for participation in a specific physiotherapy and rehabilitation protocol for 2–7 months.

Results

Minimum follow-up was 6 months; all patients were included in the postoperative follow-up evaluation. Both the donor and the recipient sites healed uneventfully. Two of the ulnar flaps showed partial necrosis (25–35%); these flaps were revised using the distal radial perforator flap (patients 6 and 12). Wound necrosis occurred in a patient two weeks after a transpalmar replantation (patient 11), and in another patient two weeks after an open injury with ulnar nerve repair (patient 5). In the first case, following meticulous debridement the median nerve was left uncovered; in the second case, a group-fascicular nerve repair of the motor branches of the ulnar nerve and neurotube interposition for bridging the two sensory branches was done. Two flaps, one radial and one ulnar (patients 25 and 26) showed 50% and 60% necrosis, respectively, and were revised by groin flaps.

The sensory and functional result was very good in 15 patients and good or satisfactory in the remainder. Range of motion of the wrist and hand joints was almost within normal limits (less than 25 degrees extension or flexion deficit). Moderate wrist stiffness with more than 25 degrees limitation of motion was observed in two patients. Complications related to the flaps including infection and non-union of the associated fractures were not observed in any patient.

Discussion

The frequency of soft hand trauma involving major tissue defects has led to the development of new classification schemes and more simple and effective treatment options.²² The regional flaps, such as the distal pedicle Chinese flap, were traditionally the surgeon's first choice whenever the local resources are exceeded. Still, this type of Chinese flap would present an important disadvantage as it involves sacrifice of a vascular axis of the hand, sometimes even the dominant one. The surgeon, would be able to avoid this inconvenience when

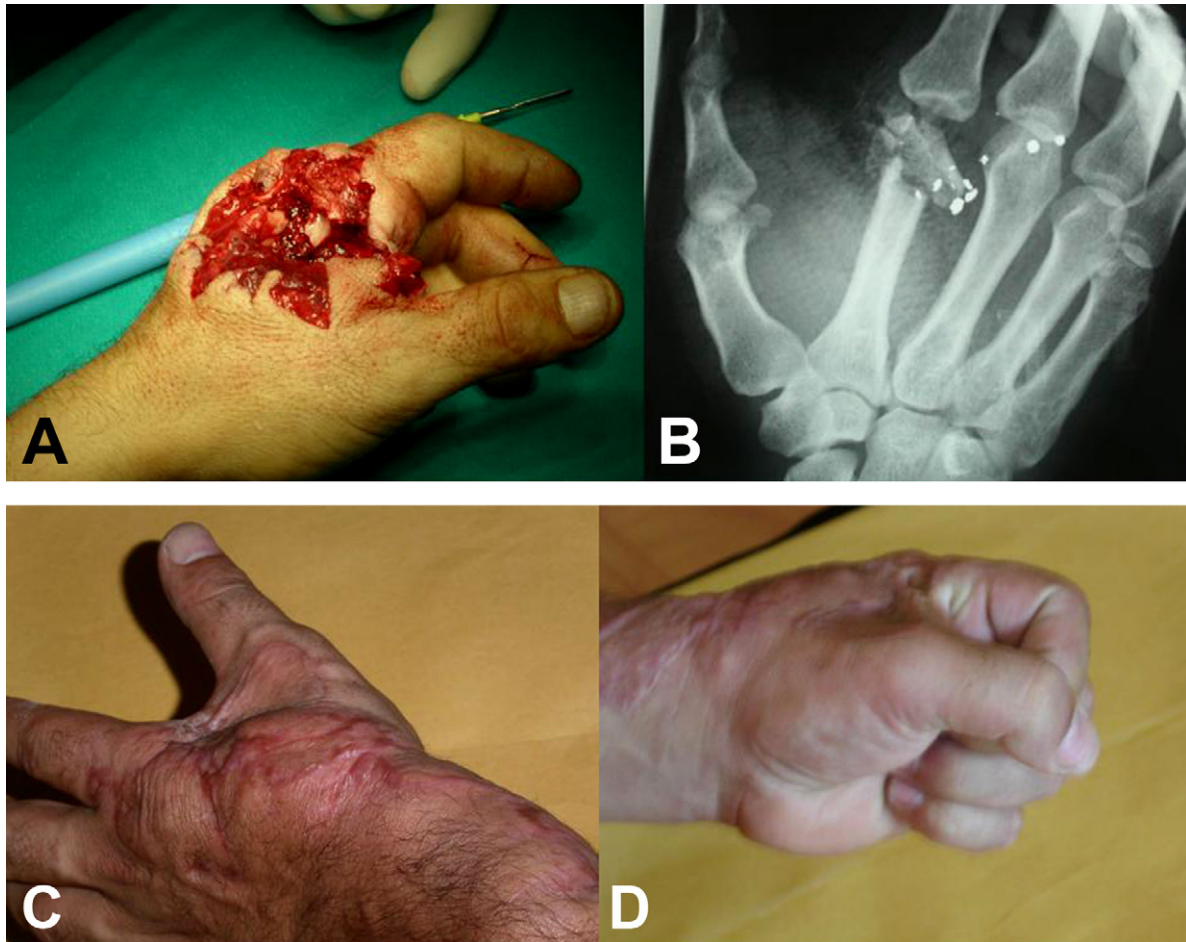


Figure 2 (A) A 24-year-old man with a gunshot injury of the left hand (patient 15). (B) Preoperative radiograph show a comminuted fracture of the second metacarpal head. One stage immediate reconstruction was done using mini external fixation of the fracture and the distal radial artery fasciocutaneous perforator-based flap. (C and D) Very good postoperative result.

using distal radial artery perforator-based flaps; moreover, these flaps would allow covering of hand defects extending as far as the metacarpophalangeal joints.¹⁸

Anatomical studies on arterial perforators have been performed using various techniques. Arterial injection techniques have been performed in all flaps studied, outlining the importance of the blood supply for the survival of the flap.^{1,21,31,33–35} In these studies, different agents have been used to show the vessels such as latex, gelatine, resin of polyesters, and radiopaque substances; each of them incorporate different characteristics that make them most appropriate to the type of vessel and to the methodology of each study. According to Rees and Taylor,³¹ to reach the best quality in an arterial injection it is important to massage from distal to proximal the vascular arbour of the regions that are going to be injected in order to empty its content, wash the vessels with warm serum and heparin before injecting latex and maintaining

the specimen submerged under water during the injecting process. In a previous study, we have used black latex to outline the perforators of the distal radial artery. An interesting technique described by Spalteholz is the transparency technique that consists in specimen fixation by the technique of alcohol and methyl salicylate clearing after latex injection of the vessels.³³ The result is a transparency elaboration of the muscular proteins that permit visualisation of the whole perforator's vascular net (Fig. 4).

Chang et al.¹⁴ described a radial forearm reverse fasciocutaneous flap that did not include the radial artery. In their report, this procedure was successful in all 10 cases of hand reconstruction in which it has been applied. The flap was a mixture of fasciocutaneous and venocutaneous muscle; the deep fascia and the cephalic vein in the pedicle had an important positive role in flap survival. To elucidate the vascular basis of this new flap, Chang and Chen^{7,10}, performed an anatomic study of 14 fresh cadaver

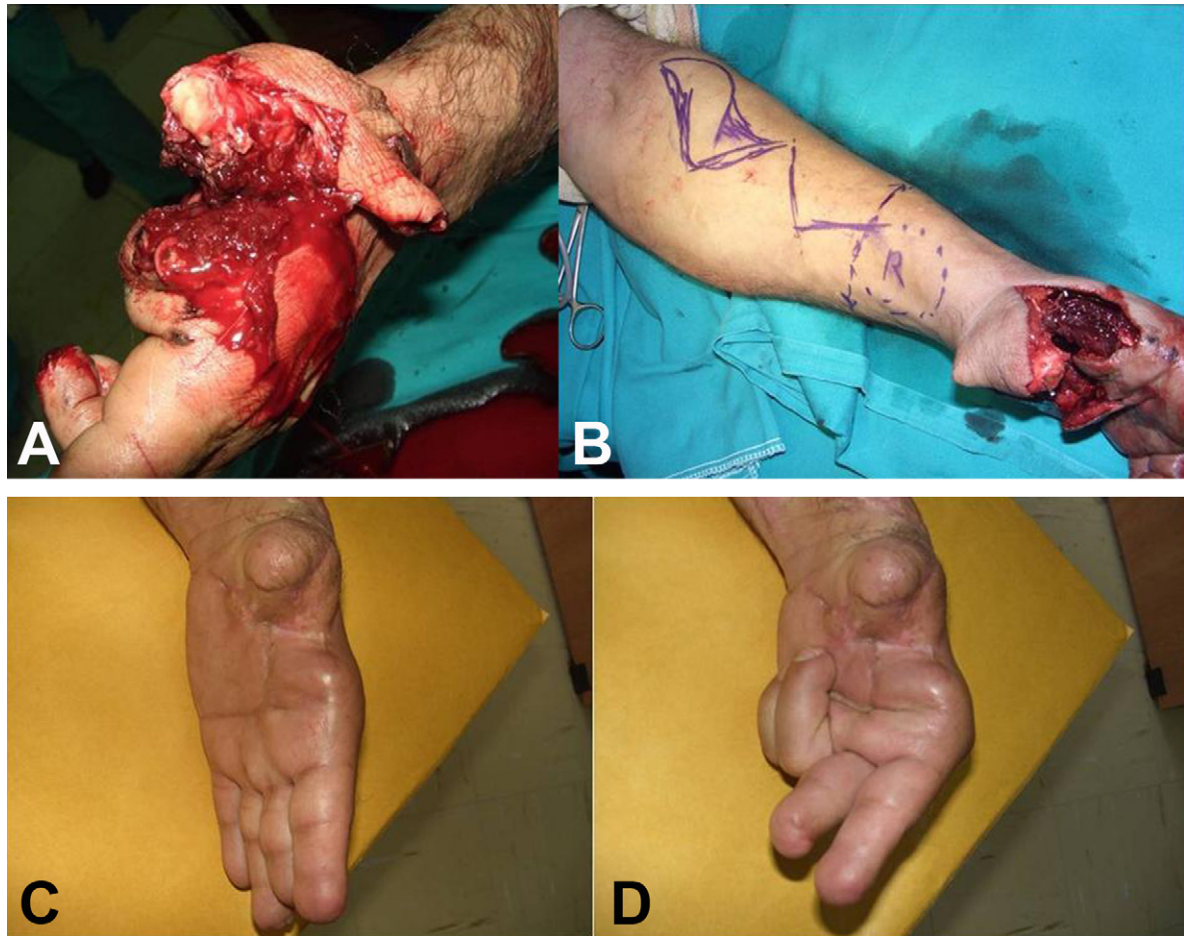


Figure 3 (A and B) A 34-year-old man with blast injury of the hand and amputation of the left thumb by fireworks (patient 16). A distal radial artery fasciocutaneous perforator flap was designed to surround the first metacarpal and reconstruct the first web space. (C and D) Very good postoperative result.

forearms, and designed a distal radial artery forearm fascial perforator flap for hand reconstruction. In their studies, they located approximately 10 small branches (0.3–0.8 mm in diameter) extending from 1.5 cm above the radial styloid process to the bifurcation of the radial artery. These perforators pass through the septum, fan out on both surfaces of the deep fascia, and form a rich, chain-linked longitudinal plexus of the integument along the course of the main artery, the septum, the fibres of the deep fascia, and the superficial vein. The venous system of the deep fascia drains blood to the profunda venae comitantes directly through the concomitant perforating veins. The pivot point of the pedicle was located 1.0–1.5 cm proximal to the radial styloid process. Chang and Chen^{11,15} also showed that the large, superficial, cephalic vein has no positive role for flap survival; it cannot help venous drainage by reverse flow through valves, but it does conduct venous blood from the hand to the flap, causing congestion and swelling that are hazardous to flap viability. Goffin et al.¹⁹ in an anatomic study of the

perforators of the distal radial artery designed a distally based island flap. These authors emphasised that the pedicle should be located 2 cm above the tip of the radial styloid process to include all the peristylod perforators.

Weinzweig et al.³⁷ reported on the distal radial artery fasciosubcutaneous perforator flap nourished by perforators originating 5–8 cm proximally to the radial styloid process. The anatomic study by Rambe and Pho³⁰ showed similar results. At the same time, Koshima et al.²⁵ described a distally based adipofascial flap for dorsal hand coverage. This flap is supplied by a lateral intertendinous perforator of the radial artery located 10 cm proximal to the radial styloid process. Braun et al.⁴ reported a distally based radial forearm fascia-fat flap supplied by distal perforators 5–8 cm above the wrist crease. They used this flap to pad and protect the median nerve, to provide a gliding surface for tendon transfer, and to separate the fresh-cut surfaces of ulna-radius synostosis. El-Khatib and Zeidan¹⁷ introduced an anatomic study of

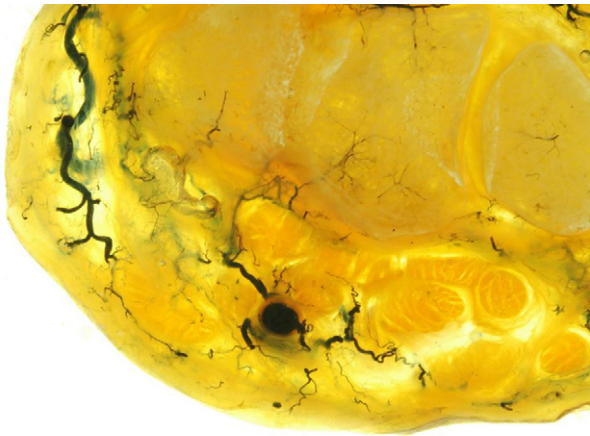

Figure 4 Radial artery transversal section with its perforators stained by black latex and elaborated by the transparency Spalteholz technique.

eight cases citing their experience using an island adipofascial flap based on distal perforators of the radial artery located 2–7 cm from the radial styloid process. Subsequently, Jeng and Wei²³ reported their clinical experience with 12 cases using the distally based radial forearm flap for hand reconstruction. The pivot point of the adipofascial pedicle was about 2–4 cm above the radial styloid process. More recently, Georgescu and Ivan¹⁸ described an extended alternative to the above flap that may be extended up to 20 cm at length. This flap has almost the same possibilities as the traditional Chinese flap to cover a distal hand defect.

The distal ulnar artery perforator-based flap can be used to cover defects of the dorsum of the wrist and hand; it can be fascial or fasciocutaneous.^{24,26} Harvesting of a fascial flap is associated with reduced donor site and flap morbidity without additional skin loss.²⁶ It has several advantages over the radial forearm flap. Flap harvesting is easy; the flexor tendons are not exposed, a major artery is not sacrificed, there is no need to perform vascular anastomoses, the donor site scar is well covered on the medial side of the forearm, and in case of failure other more intricate flap can be easily employed. The distal ulnar artery fascial perforator-based flap is indicated for the coverage of defects in areas where increased mobility of the underlying structures exists. It can also be used to cover both hand and forearm defects designed as a distally or proximally based island flap, respectively. The flap dimensions are 20 cm in length and 9 cm in width, with the ulna lying at its median axis. The flap can also be based on the proximal perforators of the ulnar artery.³⁸ A disadvantage that limits the flap rotation arc of the flap is the small length of its

pedicle (approximately 3 cm). In our patients, the extended variant of this flap (up to the middle of the forearm) was employed; this proved sufficient to cover the proximal third of the midpalm and hypothenar and more than the proximal 2/3 of the dorsum of the hand.

The same principles of flap vascular supply via perforators can be applied in the radial forearm perforator flap that is an adipofascial radial flap based on perforators of the radial artery.^{17,26} The small arterial branches and the longitudinal chain-linked vascular plexuses (suprafascial, paraneural, and perivenous) formed by the forearm ascending and descending branches of septofasciocutaneous perforators meet and cross over with the transverse carpal vascular plexuses around the radial styloid region.^{13,27} In the present series, based on these directional-oriented plexuses, distal radial artery adipofascial pedicled fasciocutaneous and adipofascial perforator flaps were designed and successfully applied in nine of our patients (in two patients after a failed distal ulnar artery perforator flap) with more than satisfactory functional results.

Variants of the distal ulnar and radial artery perforator-based flap have also been described such as the neurocutaneous island flap of the dorsal branch of the ulnar nerve based on cutaneous perforators of the distal ulnar artery,^{17,29} and the neurocutaneous, neurofascioseptocutaneous or tubed vascularised flaps based on the distal radial perforators.^{2,3,8,12,16,20,28,32}

In the present study, we used the distal ulna and radial arteries adipofascial perforator flaps to reconstruct major dorsal and palmar defects of the hand. The ulnar fascial flap was mainly used to cover defects on the palmar surface of the wrist, especially when well-vascularised tissue was needed to cover the median nerve, which may be surrounded by dense scar tissue following previous injury or surgery. The distal radial perforator-based flap is more adequate for covering defects of the radial area of the dorsal or palmar aspect of the hand or the lateral aspect of the wrist.

Conclusion

Distal ulnar and radial artery fascial or adipofascial perforator flaps are extremely useful for the reconstruction of severe dorsal and palmar defects of the hand and easy to harvest, with good results and low donor site morbidity. The blood supply is based on the perforators of the distal ulna and radial arteries in the hand and wrist. If necessary, a skin paddle can be added to these flaps. The covering ability may range from an individual finger to the entire dorsum

of the hand. By using these flaps, the need for a lengthy free flap procedure, the meticulous dissection required for the posterior interosseous flap, and the sacrifice of the radial artery for the classic radial forearm flap are avoided.

Conflict of interest

The authors declare that no funding was received and that there is no conflict of interest in this study.

References

- Bergeron L, Tang M, Morris SF. A review of vascular injection techniques for the study of perforator flaps. *Plast Reconstr Surg* 2006;117(6):2050–7.
- Bertelli JA. Neurocutaneous axial island flaps in the forearm: Anatomical, experimental, and preliminary clinical results. *Br J Plast Surg* 1993;46:489.
- Bertelli JA, Kalemli T. Retrograde-flow neurocutaneous island flaps in the forearm: Anatomic basis and clinical results. *Plast Reconstr Surg* 1995;95:851.
- Braun RM, Rechner M, Neill-Cage DJ, Schorr RT. The retrograde radial fascial forearm flap: Surgical rationale, technique, and clinical application. *J Hand Surg Am* 1995;20:915.
- Casoli V, Verolino P, Pelissier P, et al. The retrograde neurocutaneous island flap of the dorsal branch of the ulnar nerve: anatomical basis and clinical application. *Surg Radiol Anat* 2004;26(1):8–13.
- Celik N, Wei FC. Technical tips in perforator flap harvest. *Clin Plast Surg* 2003;30(3):469–72.
- Chang SM. The distally based radial forearm fascia flap. *Plast Reconstr Surg* 1990;85:150.
- Chang SM. The pedicle of neurocutaneous island flaps. *Plast Reconstr Surg* 1996;98:374.
- Chang SM. The development of the distally based radial forearm flap in hand reconstruction with preservation of the radial artery. *Plast Reconstr Surg* 2000;106(4):955–7.
- Chang SM, Chen ZW. The distally based radial forearm fascia flap without the radial artery. *Chin J Microsurg* 1990;13:143.
- Chang SM, Chen ZW. Can superficial veins reverse flow through valves in distally based fasciocutaneous flaps? *Plast Reconstr Surg* 1991;87:995.
- Chang SM, Hou CL. Integument flaps incorporating the nuturing arteries of cutaneous nerves and/or cutaneous veins. *Plast Reconstr Surg* 1999;104:1210.
- Chang SM, Hou CL, Zhang F, Lineweaver WC, Chen ZW, Gu YD. Distally based radial forearm flap with preservation of the radial artery: anatomic, experimental, and clinical studies. *Microsurgery* 2003;23(4):328–37.
- Chang YT, Wang XF, Zhou ZF, Di SY, Sun YC, Chang J. The reversed forearm island fasciocutaneous flap in hand reconstruction: Ten successful cases. *Chin J Plast Surg Burns* 1988;4:41.
- Chang SM, Zhang LS, Han PL, Chen DS. Distally based radial forearm turnover fasciosubcutaneous-fat flap for coverage of soft-tissue defects of the hand. *Chin J Hand Surg* 1993;9:82.
- Coskunfirat OK, Velidedeoglu H, Kucukcelebi A. Reversed neurofasciocutaneous flaps based on the superficial branches of the radial nerve. *Ann Plast Surg* 1999;43:367.
- El-Khatib H, Zeidan M. Island adipofascial flap based on distal perforators of the radial artery: an anatomic and clinical investigation. *Plast Reconstr Surg* 1997;100(7):1762–6.
- Georgescu A, Ivan O. Radial antibrachial islet flap based on distal perforating arteries. A clinical case. *Ann Chir Plast Esthet* 2000;45(1):58–61.
- Goffin D, Brunelli F, Galbiatti A, Sammut D, Gilbert A. A new flap based on the distal branches of the radial artery. *Ann Hand Surg* 1992;11:217.
- Hallcock GG. "Microleaps" in the progress of flaps and grafts. *Clin Plast Surg* 1996;23:117.
- Heymans OY, Nélissen XP, Peters S, Lemaire V, Carlier A. New approach to vascular injection in fresh cadaver dissection. *J Reconstr Microsurg* 2004;20(4):311–5.
- Ignatiadis IA, Yiannakopoulos CK, Mavrogenis AF, Nomikos GN, Spyridonos SG, Gerostathopoulos NE, Soucacos PN. Severe upper limb injuries with or without neurovascular compromise in children and adolescents—analysis of 32 cases. *Microsurgery* 2008;28(2):131–7.
- Jeng SF, Wei FC. The distally based forearm island flap in hand reconstruction. *Plast Reconstr Surg* 1998;102:400.
- Koshima I, Iino T, Fukuda H, Soeda S. The free ulnar forearm flap. *Ann Plast Surg* 1987;18(10):24–9.
- Koshima I, Moriguchi T, Etoh H, Tsuda K, Tanaka H. The radial artery perforator-based adipofascial flap for dorsal hand coverage. *Ann Plast Surg* 1995;35:474.
- Masquelet A, Gilbert A. The fascial flap. In: Masquelet A, Gilbert A, editors. *An atlas of flaps in limb reconstruction*. UK: Martin Dunitz; 1995. p. 78–82.
- Medalie DA. Perforator-based forearm and hand adipofascial flaps for the coverage of difficult dorsal hand wounds. *Ann Plast Surg* 2003;50(1):103–4.
- Nakajima H, Imanishi N, Fukuzumi S, Minabe T, Aiso S, Fujino T. Accompanying arteries of the cutaneous veins and cutaneous nerves in the extremities: anatomical study and a concept of the venoadipofascial and/or neuroadipofascial pedicled fasciocutaneous flap. *Plast Reconstr Surg* 1998;102:779.
- Oppikofer C, Buchler U, Schmid E. The surgical anatomy of the dorsal carpal branch of the ulnar artery: basis for a neurovascular dorsoulnar pedicled flap. *Surg Radiol Anat* 1992;14(2):97–101.
- Rambe B, Pho RWH. Distal radial fasciocutaneous flap. *Ann Acad Med Singapore* 1995;24:77.
- Rees MJ, Taylor GI. A simplified lead oxide cadaver injection technique. *Plast Reconstr Surg* 1986;77(1):141–5.
- Smith PJ, Ross DA. Tubed radial fascial flap and reconstruction of the flexor apparatus in the forearm. *J Hand Surg Am* 1993;18:959.
- Steinke H, Wolff W. A modified Spalteholz technique with preservation of the histology. *Ann Anat* 2001;183(1):91–5.
- Tan BK, Ng RT, Tay NS, Tan BS. Tissue microangiography using a simplified barium sulphate cadaver injection technique. *Ann Acad Med Singapore* 1999;28(1):152–4.
- Thiel W. An arterial substance for subsequent injection during the preservation of the whole corpse. *Ann Anat* 1992;174(3):197–200.
- Uda K, Harii K, Satake B, Yoshizumi T. Alternative use of medial and posterior upper-arm flaps. *J Reconstr Microsurg* 1998;14(5):347–53.
- Weinzweig N, Chen L, Chen ZW. The distally based radial forearm fasciosubcutaneous flap with preservation of the radial artery: an anatomic and clinical approach. *Plast Reconstr Surg* 1994;94:675.
- Yii NW, Niranjana NS. Fascial flaps based on perforators for reconstruction of defects in the distal forearm. *Br J Plast Surg* 1999;52(7):534–40.