



**POSTRAUMATIC NEUROMA OF THE RADIAL NERVE TREATED
WITH AN AUTOGENOUS EPINEURAL CONDUIT TECHNIQUE.
A CASE REPORT.**

Journal:	<i>Microsurgery</i>
Manuscript ID:	draft
Wiley - Manuscript type:	Clinical Article
Date Submitted by the Author:	n/a
Complete List of Authors:	IGNATIADIS, IOANNIS YIANNAKOPOULOS, CHRISTOS GEROSTATHOPOULOS, NIKOLAOS
Keywords:	epineurium, nerve graft , neuroma, regeneration

1
2
3
4
5
6
7
8
9
10
11
12
13
14
15
16
17
18
19
20
21
22
23
24
25
26
27
28
29
30
31
32
33
34
35
36
37
38
39
40
41
42
43
44
45
46
47
48
49
50
51
52
53
54
55
56
57
58
59
60

**POSTRAUMATIC NEUROMA OF THE RADIAL NERVE TREATED
WITH AN AUTOGENOUS EPINEURAL CONDUIT TECHNIQUE.
A CASE REPORT.**

Running Title: Autogenous Epineural Conduit Technique

I. A. Ignatiadis, C.K. Yiannakopoulos, N.E. Gerostathopoulos

Hand Surgery, Upper Limb and Microsurgery Department, KAT Hospital, Athens, Greece

Corresponding Author:

Ioannis A. Ignatiadis, M.D.
Consultant Orthopaedic and Hand Surgeon
Department of Hand Surgery and Microsurgery
KAT Hospital,
Nikis 2, 15125 Kifissia,
Athens, Greece.
Tel: +30 2106280233
Fax: +30 2106280374
Mobile: +30 6944251529
E-mail: ignatioa@yahoo.com

No benefits in any form have been received or will be received from a commercial party related directly or indirectly to the subject of this article.

Text word count: 1049

Abstract word count: 123

Number of figures: 4

ABSTRACT

We present the outcome of the first clinical application of a new technique using an epineural flap to bridge a short nerve defect. A 28-year old male had suffered a radial nerve laceration at the lower third of the arm, 3 weeks before surgery. During surgery a neuroma-in-continuity was excised preserving the epineural sleeve. Two longitudinal epineural flaps were created, one from the proximal and one from the distal nerve stump and used to bridge a 1 cm long nerve defect. Each epineurium flap was sutured to the intact epineurium of the other side and additionally to each other. An electromagnetic nerve stimulator was used to enhance the nerve regeneration process. Nerve regeneration was followed up for 12 months with excellent functional results.

KEYWORDS: epineurium, nerve graft, neuroma, regeneration

INTRODUCTION

Primary nerve repair after trauma is desirable in all cases but occasionally it is not possible. [1, 2] The reconstruction of a peripheral nerve defect after trauma or excision of a neuroma in adults and adolescents remains an insufficiently solved problem. [1, 2] In such cases nerve grafting or bridging of the defect is indicated. The ensuing defect can be bridged using a variety of autologous, heterologous or synthetic materials. [3, 4] The purpose of all bridging materials is to assist and guide axon regeneration and most materials employed are usually tubular in shape although filamentous materials such as collagen have been also used. [5, 6, 7] Although autologous nerve grafting using usually the sural nerve graft is the most satisfactory technique its use is limited by the quantity of the nerve graft material and the accompanying secondary morbidity from the harvesting technique and the eventual nerve loss.

The epineurium is a biologically active membrane surrounding the nerve and contributes significantly to its function. It has been used in animals [8, 9, 10, 11, 12, 13] to bridge nerve defects.

We describe the first clinical application of an epineural flap technique, experimentally validated in rabbits [8, 9], in a patient with short radial nerve defect after excision of a neuroma in continuity.

CASE REPORT

A 28-year old male patient suffered a radial nerve laceration at the lower third of his left arm, by a knife 3 weeks before presentation. Due to complete loss of the radial nerve function the patient was admitted for surgical exploration of the wound. During the operation the initial wound was extended proximally and distally and the radial nerve was carefully explored under magnification and dissected proximally and distally. A neuroma in continuity, 2.5 cm in length, was exposed and carefully dissected free from normal to abnormal tissue (Fig. 1). The neuroma and scar tissue were resected to healthy tissue to prevent new scar tissue formation in the proximal and distal nerve stumps. Care was taken to avoid injury to the epineurium. The two nerve stumps were approximated and held with 10-0 nylon sutures leaving a 1 cm long nerve defect.

The epineurium was then incised longitudinally in the proximal and distal stumps creating two 1.5 cm long epineural flaps one from the proximal and another one from the distal nerve stump (Fig. 2). The epineurium was plicated serving as an additional mechanical aid to bridge the nerve gap, reducing the nerve tension. The flaps were stitched to the epineurium of the other side and finally each to other with side to side stitches. The gap between the nerve stumps was filled with a blood clot from the patient's blood (Fig. 3).

1
2 Postoperatively, immobilization with a posterior splint was used for 4 weeks. Wound healing
3 proceeded uneventfully. A series of static and dynamic splinting was used accompanying
4 regular physiotherapy sessions. Supplementary, an electromagnetic nerve stimulator
5 (Compex, Chantonnay, France) was used to enhance nerve regeneration. The device was
6 applied in 7 minute sessions every second day for four months.
7
8

9
10 The efficacy of the repair was assessed by the recovery of wrist, thumb and finger mobility
11 and by the progression of Tinel's sign. The Tinel's sign was progressing for the first 5 months
12 and was followed by gradual recovery of the extensor muscle strength. Evaluation of the
13 results was performed using the Medical Research Council Method, measuring both motor
14 and sensory recovery. Motor recovery of the radial nerve was measured by the activity of the
15 wrist, finger and thenar extensor muscles, which demonstrated M4 (excellent) 9 months
16 postoperatively (Fig. 4). Sensory recovery at the area of the superficial radial nerve at the
17 second metacarpal area was S3.
18
19
20
21
22
23

24 25 DISCUSSION

26
27
28 Although autologous nerve grafting is currently the recommended technique for
29 reconstructing nerve gaps, normal function is not always restored and results are not
30 excellent. [1, 2] After a peripheral nerve laceration a large defect may arise between the
31 proximal and distal nerve segments. In certain cases harvesting or sacrifice of autologous
32 nerves is not feasible or wanted and in such cases a nerve conduit has to be used. [3-5]
33 Various types of nerve conduits have been tested for the purpose of restoring a nerve defect
34 including iso-, allo-, or xenografts, absorbable or non absorbable materials, collagen, tendons
35 etc.
36
37
38
39
40

41
42 The idea of using the epineurium to bridge a nerve defect is not new. Several experimental
43 studies in animals supported the idea of using the epineurium in nerve reconstructive
44 surgery. [8, 9, 10, 11, 12, 13]
45

46 The epineurium tube protects the regeneration site from undesirable external humoral
47 influences providing a positive regeneration environment. The interposed epineurium is not
48 just a passive conduit but it may assume a more active role in the nerve regeneration process
49 by providing neurotrophic factors. Additionally the axoplasmic fluid is retained at the repair
50 site and this facilitates the regeneration process.
51

52 The use of epineurium has several advantages: a neural origin conduit is used; no separate
53 surgical exposure for harvesting is necessary; there is no donor-recipient size mismatch; the
54 biocompatibility is perfect; there no antigenicity or inflammatory reaction and the cost of
55 harvesting is negligible. Disadvantages are that the intraoperative surgical management of the
56 epineurium is technically difficult, the harvesting procedure is time consuming and
57 demanding and the amount of the graft material is limited. A concern is that stripping of the
58
59
60

1
2 epineurium might influence nerve electrophysiologic properties. Denuding of the sciatic nerve
3 from the epineurium in the rat did not induce significant alterations in the nerve function. [10]
4 In our animal studies [8, 9] unlike all other similar studies the epineurial tube was not left
5 empty but it was filled with a blood clot to prevent lumen collapse. Failure to fill the tube may
6 partly account for some of the unsuccessful results in previous experiments. Furthermore,
7 filling the conduit chamber with growth factors or exogenous matrix precursors may promote
8 regeneration although filling of a short epineurial sleeve with fibrin glue did not make any
9 functional difference. [13]
10
11
12
13
14
15
16

17 CONCLUSION

18 In special circumstances the use of an epineural flap may be useful for bridging short nerve
19 defects in humans. The procedure may be accompanied by the use of neurotrophic factors to
20 promote nerve regeneration. The epineurium serves as a mechanical means to reduce the gap
21 size, to increase the repair strength and to effectively assist nerve regeneration.
22
23
24
25
26

27 REFERENCES

- 28 1. Lundborg G. 2005. Nerve injury and repair, 2nd Edition, Churchill Livingstone, pp 33-
29 36.
- 30 2. Portincasa A, Gozzo G, Parisi D, Annacontini L, Campanale A, Basso G, Maiorella A.
31 Microsurgical treatment of injury to peripheral nerves in upper and lower limbs: a
32 critical review of the last 8 years. *Microsurgery*. 2007; 27: 455-62.
- 33 3. Strauch B. Use of nerve conduits in peripheral nerve repair. *Hand Clinics* 2000; 16:
34 123-130.
- 35 4. Nicoli Aldini N, Fini M, Rocca M, Giavaresi G, Giardino R. Guided regeneration with
36 resorbable conduits in experimental peripheral nerve injuries. *Int Orthop*. 2000;
37 24(3):121-125.
- 38 5. Battiston B, Geuna S, Ferrero M, Tos P. Nerve repair by means of tubulization: literature
39 review and personal clinical experience comparing biological and synthetic conduits
40 for sensory nerve repair. *Microsurgery*. 2005; 25: 258-267.
- 41 6. Donoghoe N, Rosson GD, Dellon AL. Reconstruction of the human median nerve in the
42 forearm with the Neurotube. *Microsurgery*. 2007; 27: 595-600.
- 43 7. Yoshii S, Oka M, Ikeda N, Akagi M, Matsusue Y, Nakamura T. Bridging a peripheral
44 nerve defect using collagen filaments. *J Hand Surg [Am]*. 2001; 26: 52-59.
- 45 8. Ignatiadis IA, Tsiampa VA, Yiannakopoulos CK, Xeinis SF, Papalois AE, Xenakis TH,
46 Beris AE, Soucacos PN. A new technique of autogenous conduits for bridging short
47
48
49
50
51
52
53
54
55
56
57
58
59
60

- 1
2 nerve defects. An experimental study in the rabbit. *Acta Neurochir Suppl.* 2007; 100:
3 73-76.
4
- 5 9. Ignatiadis IA, Yiannakopoulos CK, Barbitsioti AD, Avram AM, Patralexis HG, Tsolakis
6 CK, Papalois AE, Xenakis TH, Beris AE, Soucacos PN. Diverse types of epineural
7 conduits for bridging short nerve defects. An experimental study in the rabbit.
8 *Microsurgery.* 2007; 27: 98-104.
9
- 10 10. Karacaoglu E, Yuksel F, Peker F, Guler MM. Nerve regeneration through an epineurial
11 sheath: its functional aspect compared with nerve and vein grafts. *Microsurgery.* 2001;
12 21:196-201.
13
- 14 11. Siemionow M, Tetik C, Ozer K, et al. Epineural sleeve neurorrhaphy: surgical technique
15 and functional results. *Ann Plast Surg* 2002; 48: 281–285.
16
- 17 12. Snyder CC, Browne EZ, Herzog BG, et al. Epineural cuff neurorrhaphy. *J Bone Joint Surg*
18 *Am* 1974; 56A: 1092
19
- 20 13. Tetik C, Ozer K, Ayhan S, Siemionow K, Browne E, Siemionow M. Conventional versus
21 epineural sleeve neurorrhaphy technique: functional and histomorphometric analysis.
22 *Ann Plast Surg.* 2002;49(4):397-403.
23
24
25
26
27
28
29
30
31
32
33
34
35
36
37
38
39
40
41
42
43
44
45
46
47
48
49
50
51
52
53
54
55
56
57
58
59
60

1
2
3
4
5
6
7
8
9 **FIGURE LEGENDS**

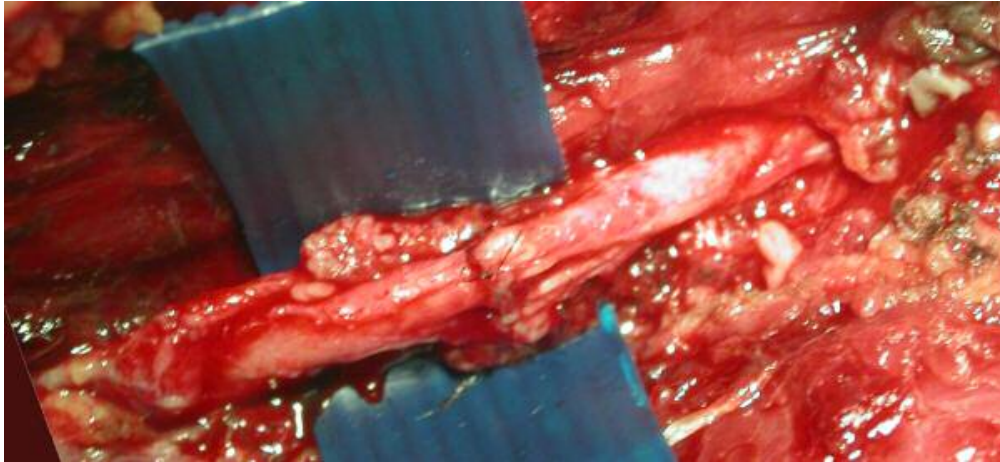
10
11
12
13
14 **Figure 1.** Intraoperative photograph of the neuroma in continuity of the radial nerve
15 (arrowhead).
16

17
18
19
20 **Figure 2.** Drawing of the surgical procedure. The neuroma was dissected free and excised,
21 preserving the epineurium (1 and 2). The nerve stumps were approximated and sutured
22 without tension leaving a 1 cm long defect (3). Two epineural flaps fashioned from the
23 proximal and the distal stumps were plicated and sutured to the each other to reduce repair
24 tension and to isolate the nerve defect area (4).
25
26

27
28
29
30 **Figure 3.** Intraoperative photograph of the sutured nerve stumps covered with the epineural
31 flaps.
32

33
34 **Figure 4.** One year after the operation the patient was able to fully extend his wrist and
35 fingers.
36
37
38
39
40
41
42
43
44
45
46
47
48
49
50
51
52
53
54
55
56
57
58
59
60


1
2
3
4
5
6
7
8
9
10
11
12
13
14
15
16
17
18
19
20
21
22
23
24
25
26
27
28
29
30
31
32
33
34
35
36
37
38
39
40
41
42
43
44
45
46
47
48
49
50
51
52
53
54
55
56
57
58
59
60



50x23mm (300 x 300 DPI)

Peer Review

1
2
3
4
5
6
7
8
9
10
11
12
13
14
15
16
17
18
19
20
21
22
23
24
25
26
27
28
29
30
31
32
33
34
35
36
37
38
39
40
41
42
43
44
45
46
47
48
49
50
51
52
53
54
55
56
57
58
59
60

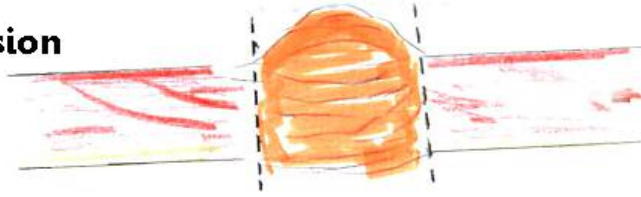

54x37mm (300 x 300 DPI)

Review

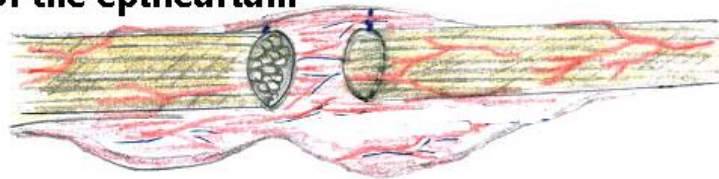
1
2
3
4
5
6
7
8
9
10
11
12
13
14

**1
neuroma excision**



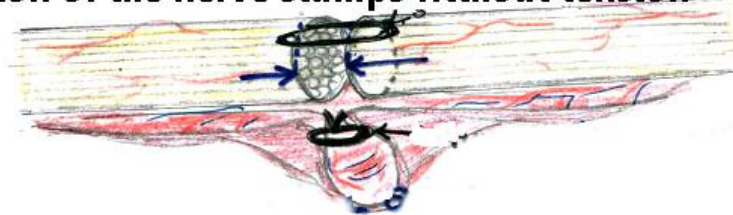
15
16
17
18
19
20
21
22

**2
preservation of the epineurium**



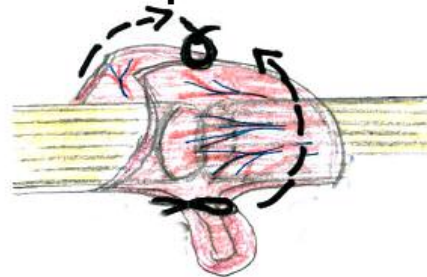
23
24
25
26
27
28
29
30
31

**3
approximation of the nerve stumps without tension**



32
33
34
35
36
37
38
39
40
41
42
43

**4
suturing of the 2 epineurium flaps**

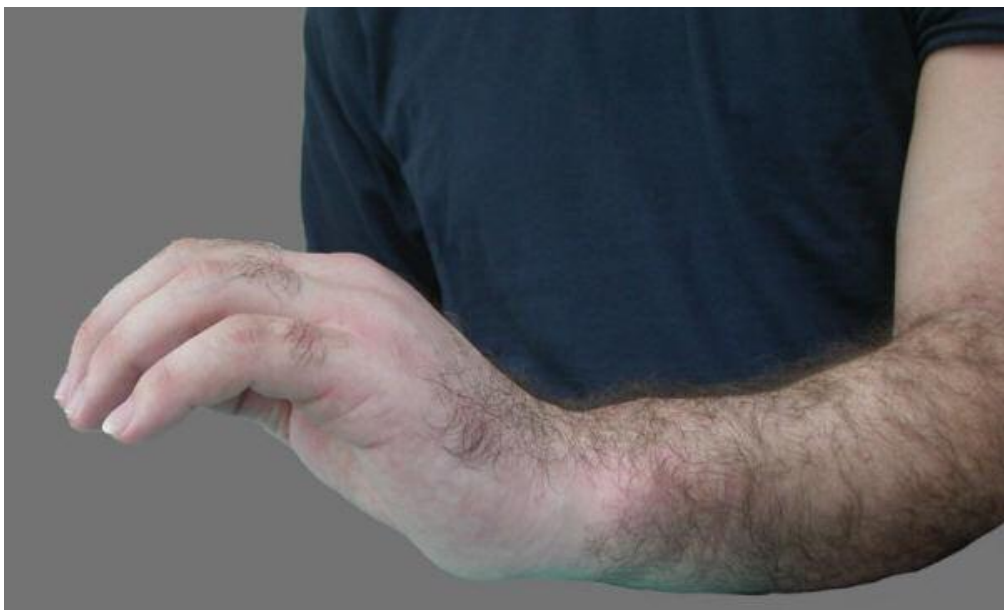

44
45
46
47
48
49
50
51
52
53
54
55
56
57
58
59
60

Drawing of the surgical procedure. The neuroma was dissected free and excised, preserving the epineurium (1 and 2). The nerve stumps were approximated and sutured without tension leaving a 1 cm long defect (3). Two epineurial flaps fashioned from the proximal and the distal stumps were plicated and sutured to the each other to reduce repair tension and to isolate the nerve defect area (4).

56x60mm (300 x 300 DPI)

1
2
3
4
5
6
7
8
9
10
11
12
13
14
15
16
17
18
19
20
21
22
23
24
25
26
27
28
29
30
31
32
33
34
35
36
37
38
39
40
41
42
43
44
45
46
47
48
49
50
51
52
53
54
55
56
57
58
59
60



One year after the operation the patient was able to fully extend his wrist and fingers.
50x30mm (300 x 300 DPI)

Review